

## Technical Note

# Marrow Stimulating Technique to Augment Meniscus Repair

Kevin B. Freedman, M.D., M.S.C.E., Shane J. Nho, B.A., and Brian J. Cole, M.D., M.B.A.

---

**Abstract:** Several techniques exist to increase the rate of healing of meniscal tears after repair. We describe a simple arthroscopic technique of microfracture to the intercondylar notch. This technique can provide marrow elements to the site of meniscus repair to aid in meniscal healing at the time of repair. **Key Words:** Meniscus repair—Microfracture—Marrow stimulation—Biologic augmentation.

---

The rate of healing after meniscus repair varies in the literature from 63% to 91%.<sup>1</sup> The rate of healing is more favorable for smaller tears, acute tears, tears repaired in stable joints, and repairs performed with concomitant anterior cruciate ligament (ACL) reconstruction.<sup>2</sup> Additionally, peripheral tears with adequate vascular supply are more likely to result in a successful repair. The vasculature of the meniscus stems from the attachment of the synovium and joint capsule and supplies the outer one-third region.<sup>3,4</sup> Meniscus tears in the well-vascularized periphery are able to mount a proper healing response, whereas tears in the poorly-vascularized center have limited healing capabilities.<sup>5,6</sup>

Several studies, both clinical and basic science, have shown increased healing of meniscal tears with the introduction of blood and marrow elements into the joint.<sup>7-9</sup> Researchers believe that meniscus repair performed in conjunction with ACL reconstruction have improved healing rates compared with the repair of isolated meniscus because of several factors, including re-establishment of knee kinematics and sta-

bility, longer rehabilitation associated with ACL reconstruction, and more extensive hemarthrosis with fibrin clot formation.<sup>2,5,8,10-14</sup> Experimental techniques to introduce intra-articular blood and marrow elements, such as fibrin clot and fibrin glue with marrow elements, also have been shown to increase the rate of meniscal healing.<sup>7,9</sup> We believe that patients undergoing meniscus repair and concomitant ACL reconstruction with intercondylar notchplasty and bone tunnels have an improved rate of healing, primarily because of the release of marrow elements into the joint.

The purpose of this article is to introduce a simple arthroscopic technique to enhance the repair of isolated meniscus tears by penetrating the subchondral bone of the intercondylar notch, thereby releasing blood and marrow elements into the joint, similar to the biologic environment presumably created during ACL reconstruction.

## SURGICAL TECHNIQUE

A standard set-up for knee arthroscopy is performed. When a possible meniscus repair is to be performed, a leg holder is used to freely access the posteromedial and posterolateral aspect of the knee. A thorough diagnostic arthroscopy is performed. When a meniscus tear is encountered, it is assessed for reparability. The ideal tear for repair is a longitudinal, full-thickness tear that is greater than 1 cm and in the red-red or red-white zone. In general, we do not repair meniscus tears in the white-white zone. The meniscus

---

*From the Section of Sports Medicine, Department of Orthopaedic Surgery, Rush Medical College, Rush-Presbyterian-St. Luke's Medical Center, Chicago, Illinois, U.S.A.*

*Address correspondence and reprint requests to Brian J. Cole, M.D., M.B.A., Rush Cartilage Restoration Center, 1725 W. Harrison St, Suite 1063, Chicago, IL 60612, U.S.A. E-mail: bcole@midwestortho.com*

© 2003 by the Arthroscopy Association of North America  
0749-8063/03/1907-3505\$30.00/0  
doi:10.1016/S0749-8063(03)00695-9

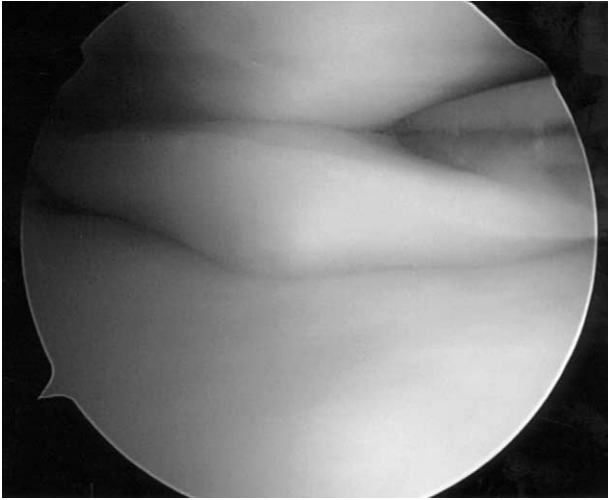


FIGURE 1. Displaced, bucket-handle tear of the medial meniscus.

is prepared by gently rasping the edges of the tear. No excessive debridement is performed. We prefer to use an inside-out suture technique whenever possible. An accessory incision is made on the posteromedial or posterolateral aspect of the knee for suture retrieval. The appropriate zone-specific cannula (Linvatec, Largo, FL) is used through the contralateral arthroscopy portal, and double-armed 2-0 Ethibond sutures (Ethicon, Somerville, NJ) are used to place vertical mattress sutures across the meniscus tear. The needles are retrieved through the accessory incision. After all sutures are placed, the sutures are tied with the knee in full extension. The repair is then inspected and probed for adequate stability (Figs 1 and 2). Occasionally, for anterior horn meniscus tears, an outside-in technique using an 18-gauge spinal needle, No. 0 polydioxanone suture (PDS, Ethicon), and a "mulberry knot" technique is used.<sup>15</sup>

After a satisfactory repair is performed, a 45° microfracture awl (Linvatec) is placed through the contralateral portal. The awl is repeatedly penetrated through the subchondral bone of the intercondylar notch at the PCL origin until marrow elements are seen to enter the joint (Figs 3 and 4). The flow of arthroscopic fluid is interrupted to better observe the marrow elements emanating from the microfracture holes.

The arthroscope is then removed. A standard closure of the accessory incision and arthroscopic portals is performed. We do not use a brace postoperatively. The patients are allowed to bear weight as tolerated, with range of motion restricted while weight-bearing

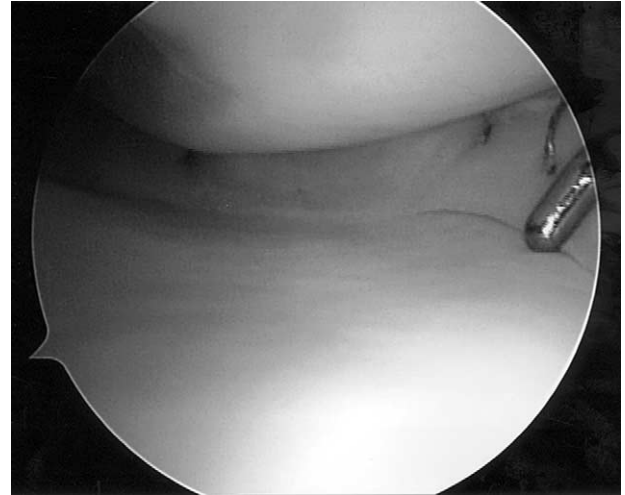


FIGURE 2. The reduced meniscus after inside-out suture repair is seen.

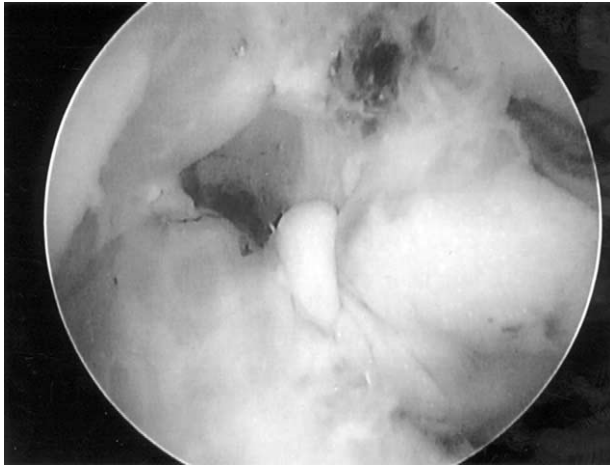
from 0° to 90° for the first 6 weeks. Full range of motion is allowed when not weight-bearing. After the first 6 weeks, full range of motion while weight-bearing is allowed, and activity is progressed as tolerated. Return to full activity is permitted at 4 to 6 months after surgery.

## DISCUSSION

The repair response for meniscal healing after injury has been well defined. The human meniscus is a fibrocartilagenous tissue composed of 2 distinct cell types imbedded in an interlacing collagen network.<sup>16</sup>

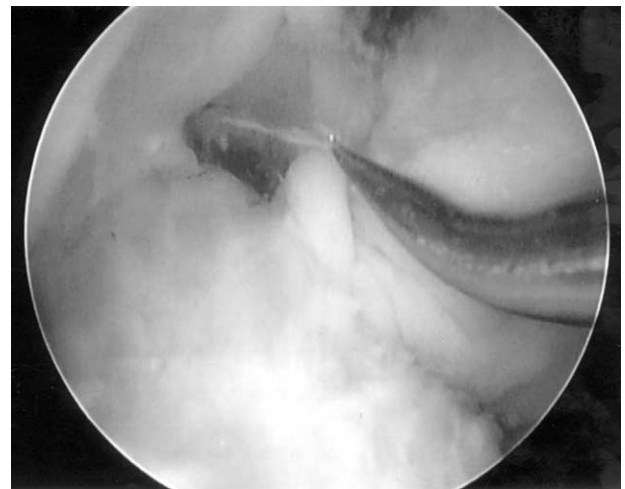

FIGURE 3. Microfracture awl in the intercondylar notch is seen.



**FIGURE 4.** Penetration of the microfracture awl in the subchondral bone at the PCL origin to induce marrow elements into the joint.

Cells of superficial surface are oval or fusiform, whereas the cells deep in the substance of the meniscus are round or polygonal.<sup>3,17</sup> Some researchers believe the morphology are suggestive of chondrocytes, but other investigators believe that the production of predominantly type I collagen is more indicative of fibrochondrocytes.<sup>18,19</sup> The exact classification of these cells remains controversial, but numerous studies have shown that the 2 cell types seem to respond uniquely to growth factors and media constituents.<sup>20-22</sup> The intrinsic repair capability of fibrochondrocytes of the vascularized periphery has been well characterized.<sup>23</sup> The tear site is infiltrated by inflammatory cells, creating a vascularized fibrin clot allowing mesenchymal cells to infiltrate the fibrin clot. The clot becomes a fibrovascular scar by 10 weeks and undergoes further remodeling until the establishment of fibrocartilagenous tissue.<sup>23</sup> Organ culture studies have shown that the cells of the avascular region do, in fact, possess an intrinsic healing response.<sup>24</sup> The meniscal fibrochondrocytes are capable of migrating in response to chemotactic and mitogenic stimuli, and they are able to proliferate and synthesize extracellular matrix in response to injury.<sup>7,25,26</sup>

The hemarthrosis resulting from ACL reconstruction with intercondylar notchplasty may augment meniscal healing by exposing the repair to marrow elements, including growth factors and mesenchymal stem cells. Insulin-like growth factor-1 (IGF-1), transforming growth factor (TGF) family, and several bone morphogenic proteins (BMPs) are responsible for the maintenance of cartilage homeostasis. IGF-1 is the major growth factor controlling matrix synthesis and

matrix degradation in healthy cartilage.<sup>27</sup> TGF- $\beta$  and BMP-2 stimulate the production of proteoglycan and promote cartilage repair.<sup>28-31</sup> The recently isolated cartilage-derived morphogenetic protein (CDMP) is involved in embryonic tissue development, and CDMP may also play a role in repair because many features resemble embryonic processes.<sup>32</sup> Marrow mesenchymal stem cells are pluripotent progenitor cells, and the ultimate phenotype of these cells depends on a number of intrinsic and extrinsic signals.<sup>33</sup> The use of autologous mesenchymal stem cells has been used in the healing of meniscus lesions in a goat model with the ability to differentiate into a cell type appropriate for matrix repair.<sup>34,35</sup> Bone marrow cells seeded in a type I collagen matrix for meniscus reconstruction in a rabbit model had enhanced repair characteristics compared with type I collagen matrices or periosteum alone.<sup>36</sup>

Tears in the avascular areas of the meniscus are less likely to result in successful healing, and there are a variety of techniques that attempt to enhance the healing of tears in these areas. One method to improve the vascular supply is by rasping the parameniscal synovium and rasping either side of the meniscus tear.<sup>1</sup> The fibrin clot has been evaluated scientifically and clinically, but the results are equivocal. Henning et al.<sup>37</sup> reported that the use of the fibrin clot decreased failures of isolated repairs from 61% to 8%, but Cannon<sup>2</sup> noted only a modest reduction in failures, from 60% to 42%. A study in dogs introduced the idea of vascular access channels to irrigate the peripheral circulation to the avascular central areas to bring about fibrovascular healing of central zones. The channel, however, disrupts the peripheral circumferential fibers, which weakens the biomechanical properties of the meniscus.<sup>23</sup> Partial thickness trephination with suture repair of peripheral menisci produced partial or complete meniscal healing, whereas no healing was noted with peripheral menisci repaired with sutures alone.<sup>38</sup> Other experimental techniques to enhance healing of meniscus repairs include synovial flap,<sup>39-42</sup> fibrin glue,<sup>9,43</sup> fibrin glue with endothelial cell growth factor,<sup>44</sup> cyanoacrylate glue,<sup>45</sup> platelet-derived growth factor,<sup>20</sup> laser stimulation,<sup>46,47</sup> and Caspari suture punch.<sup>48</sup> None of the existing techniques have produced overwhelming results to date. The most significant aspect of enhancing meniscal healing appears to be the addition of blood and particularly marrow elements with pluripotential stem cells.<sup>9</sup>

The described technique of microfracture to the intercondylar notch is a simple way to provide marrow elements to the site of meniscus repair to aid in me-

niscal healing at the time of repair. This technique does not require additional skills or novel arthroscopic devices. Further basic science studies are critical to objectively evaluate the effects of marrow elements on the site of meniscus repair, as well as further clinical studies to validate the efficacy of this technique.

## REFERENCES

- DeHaven K. Meniscus repair. *Am J Sports Med* 1999;27:242-250.
- Cannon WDJ. Arthroscopic meniscal repair. In: McGinty JB, Caspari RB, Jackson RW, Poehling GG, eds. *Operative arthroscopy*. Philadelphia: Lippincott-Raven, 1996.
- Ghadially FN, Lalonde JM, Wedge JH. Ultrastructure of normal and torn menisci of the human knee joint. *J Anat* 1983; 136:773-791.
- McDevitt CA, Webber RJ. The ultrastructure and biochemistry of meniscal cartilage. *Clin Orthop* 1990;252:8-18.
- Cooper D, Arnoczky S, Warren R. Arthroscopic meniscal repair. *Clin Sports Med* 1990;9:589-607.
- DeHaven K. Decision-making factors in the treatment of meniscal lesions. *Clin Orthop* 1990;252:49-54.
- Arnoczky SP, Warren RF, Spivak JM. Meniscal repair using an exogenous fibrin clot: An experimental study in dogs. *J Bone Joint Surg Am* 1988;70:1209-1217.
- Cannon WDJ. The incidence of healing in arthroscopic meniscal repairs in anterior cruciate ligament-reconstructed knees versus stable knees. *Am J Sports Med* 1992;20:176-181.
- Ishimura M, Ohgushi H, Habata T. Arthroscopic meniscal repair using fibrin glue: Part I: Experimental study. *Arthroscopy* 1997;13:551-557.
- Barber F, Click S. Meniscus repair rehabilitation with concurrent anterior cruciate ligament reconstruction. *Arthroscopy* 1997;13:433-437.
- Morgan C, Wojtys E, Casscells C, Casscells S. Arthroscopic meniscal repair evaluated by second-look arthroscopy. *Am J Sports Med* 1991;19:632-637.
- van Trommel M, Simonian P, Potter H, Wickiewicz T. Different healing rates with the outside-in technique for meniscal repair. *Am J Sports Med* 1998;26:446-452.
- Bach BR, Warren RF, Wickiewicz TL. The pivot shift phenomenon: Results and descriptions of a modified clinical test for anterior cruciate ligament insufficiency. *Am J Sports Med* 1988;16:571-576.
- Jonsson H, Karrholm J, Elmqvist LG. Kinematics of active knee extension after tear of the anterior cruciate ligament. *Am J Sports Med* 1989;17:796-802.
- Warren RF. Arthroscopic meniscus repair. *Arthroscopy* 1985; 1:170-172.
- Arnoczky SP. Building a meniscus. *Clin Orthop* 1999;367S: 244-253.
- Ghadially FN, Thomas I, Yong N, Lalonde JMA. Ultrastructure of rabbit semilunar cartilages. *J Anat* 1978;125:499-517.
- McDevitt CA, Miller RR, Spindler KP. The cells and cell matrix interaction of the meniscus. In: Mow VC, Arnoczky SP, Jackson DW, eds. *Knee meniscus: Basic and clinical foundations*. New York: Raven Press, 1992.
- Webber RJ, Norby DP, Malesud CJ, et al. Characterization of newly synthesized proteoglycans from rabbit menisci in organ culture. *Biochem J* 1984;221:875-884.
- Spindler KP, Mayes CE, Miller RR. Regional mitogenic response of the meniscus to platelet-derived growth factor (PDGF-AB). *J Orthop Res* 1995;13:201-205.
- Webber RJ, Harris MG, Hough AJ. Cell culture of rabbit meniscal fibrochondrocytes: Proliferative and synthetic response to growth factors and ascorbate. *J Orthop Res* 1985;3: 36-42.
- Webber RJ, Zitaglio T, HA J. In vitro cell proliferation and proteoglycan synthesis of rabbit meniscal fibrochondrocytes as a function of age and sex. *Arthritis Rheum* 1986;29:1010-1016.
- Arnoczky SP, Warren RF. The microvasculature of the meniscus and its response to injury: An experimental study in the dog. *Am J Sports Med* 1983;11:131-141.
- Noyes FR, Barber-Westin SD. Arthroscopic repair of meniscus tears extending into the avascular zone with or without anterior cruciate ligament reconstruction in patients 40 years of age and older. *Arthroscopy* 2000;16:822-829.
- Webber RJ, York JL, Vander Schilde JL, Hough AJ. An organ culture system for assaying wound repair of the fibrochondrocytes knee joint meniscus. *Am J Sports Med* 1989;17:393-400.
- Arnoczky SP. Gross and vascular anatomy of the meniscus and its role in the meniscal healing, regeneration, and remodeling. In: Mow VC, Arnoczky SP, Jackson DW, eds. *Knee meniscus: Basic and clinical foundations*. New York: Raven, 1992.
- van den Berg WB, van der Kraan PM, Scharstuhl A, van Beuningen HM. Growth factors and cartilage repair. *Clin Orthop* 2001;391S:244-250.
- Glansbeek HL, van der Kraan PM, Ve I. Correlation of the size of type II transforming growth factor  $\beta$  (TGF- $\beta$ ) receptor with TGF- $\beta$  responses of isolate bovine articular chondrocytes. *Ann Rheum Dis* 1993;52:812-816.
- Glansbeek HL, van Beuningen HM, Ve L. Bone morphogenetic protein-2 stimulates articular cartilage proteoglycan synthesis in vivo but does not counteract IL-1 $\mu$  effects on proteoglycan synthesis and content. *Arthritis Rheum* 1997;40: 1020-1028.
- van Beuningen HM, van der Kraan PM, Arntz OJ. Transforming growth factor- $\mu$ 1 stimulates articular chondrocyte proteoglycan synthesis and induces osteophyte formation in muring knee joint. *Lab Invest* 1994;71:279-290.
- van der Kraan PM, Vitters EL, van Beuningen HM. Role of nitric oxide in the inhibition of BMP-2-mediated stimulation of proteoglycan synthesis in articular cartilage. *Osteoarthritis Cartilage* 2000;8:82-86.
- Erlacher L, Ng CK, Ulrich R. Presence of cartilage-derived morphogenetic proteins in articular cartilage and enhancement of matrix replacement in vitro. *Arthritis Rheum* 1998;41:263-273.
- Caplan AI. Mesenchymal stem cells. *J Orthop Res* 1991;9: 641-650.
- Port J, Jackson DW, Lee QL, Simon TM. Meniscal repair supplemented with exogenous fibrin clot and autogenous cultured marrow cells in the goat model. *Am J Sports Med* 1996;24:547-555.
- Caplan AI, Bruder SP. Cell and molecular engineering of bone regeneration. In: Lanza RP, Langer R, Chick WL, eds. *Principles of tissue engineering*. Austin: RG Landes, 1998.
- Walsh CJ, Goodman D, Caplan AI, Goldberg VM. Cell-based meniscus regeneration in a partial meniscectomy model. *Trans Orthop Res Soc* 1996;21:100.
- Henning CE, Lynch MA, Yearout KM. Arthroscopic meniscal repair using an exogenous fibrin clot. *Clin Orthop* 1990;252: 64-72.
- Zhang Z, Artold JA, Williams T. Repairs by trephination and suturing of longitudinal injuries in the avascular area of the meniscus in goats. *Am J Sports Med* 1995;23:35-41.
- Cisa J, Basora J, Madarnas P. Meniscal repair by synovial flap transfer: Healing of the avascular zone in rabbits. *Acta Orthop Scand* 1995;66:38-40.
- Jitsuiki J, Onchi M, Ikuta Y. Meniscal repair enhanced by an interpositional free synovial autograft: An experimental study in rabbits. *Arthroscopy* 1994;10:659-666.
- Kobuna Y, Shirakuar K, Nijijima M. Meniscal repair using a

- flap of synovium: An experimental study in the dog. *Am J Knee Surg* 1995;8:52-55.
42. Onchi M, Mochizuki Y, Deie M. Augmented meniscal healing with free synovial autografts: An organ culture model. *Arch Orthop Trauma Surg* 1996;115:123-126.
  43. Ishimura M, Tamai S, Fugisawa Y. Arthroscopic meniscal repair with fibrin glue. *Arthroscopy* 1991;7:177-181.
  44. Hashimoto J, Kurosaka M, Yoshiya S. Meniscal repair using fibrin sealant and endothelial cell growth factor: An experimental study in dogs. *Am J Sports Med* 1992;20:537-541.
  45. Koukoubis TD, Glisson RR, Feagin JAJ. Augmentation of meniscal repairs with cyanoacrylate glue. *J Biomed Mater Res* 1995;29:715-720.
  46. Forman SK, Oz MC, Lontz JF. Laser-assisted fibrin clot soldering of human menisci. *Clin Orthop* 1995;301:37-41.
  47. Vangsnes CTJ, Akl Y, Marchall GJ. The effects of the neodymium laser on meniscal repair in the avascular zone of the meniscus. *Arthroscopy* 1994;10:201-205.
  48. Tao SS, Beach WR. Use of a Caspari suture punch to repair a radial tear of the lateral meniscus. *Arthroscopy* 2002;18:206-210.